



STEMI Education for Emergency Department



Purpose

To standardize emergency department management of ST elevation myocardial infarction (STEMI) across the province by reinforcing the STEMI reperfusion targets and best practices to improve patient outcomes.



CCN History and Mandate

- CCN has a solid history of advising the Ministry of Health and Long-Term Care (MOHLTC), Local Health Integration Networks (LHINs), hospitals and care providers to improve the quality, efficiency, accessibility and equity of cardiac services for patients across Ontario. Currently, CCN's mandate has expanded to include the management of vascular and more recently stroke services for patients and providers in Ontario.
- CCN supports the system by :
 - System Capacity Planning, Performance Measurement and Management
 - Developing and Implementing Best Practice Standards from Evidence and Research:
 - Cardiac and Vascular Surgical Procedures
 - Heart Rhythm and Heart Failure Management
 - Interventional Cardiology, STEMI
 - Stroke and Hypertension Management
 - Prevention, Rehabilitation, & Palliative Care
 - Evaluation of Emerging Technologies
 - Managing the Cardiac and Vascular Registries which is a robust information source of patient clinical data to inform stakeholders



STEMI Care in Ontario

- In Ontario, approximately 8,000 patients per year experience an ST-segment elevation myocardial infarction (**STEMI**)
- Today, **16 Primary PCI hospitals with STEMI programs** are located across Ontario
- Approximately **40% of STEMI patients self transport to ED**
- Restoration of blood flow in the coronary artery is achieved through **one of the following** best practice reperfusion modalities:
 1. Primary percutaneous coronary intervention (pPCI)
 2. Pharmacoinvasive Intervention (Fibrinolytic therapy plus PCI in 24 hrs)
- Reperfusion requires **timely diagnosis, transportation and treatment**
- The goal of the ED STEMI protocol is to ensure a baseline standard of best practice care for all STEMI patients to **receive timely access to reperfusion therapy** regardless of where they present



Objectives

Upon completion of this education the learner will be able to:

- Name the typical and atypical signs and symptoms of acute coronary syndrome (ACS)
- Describe the importance of acquiring a rapid ECG in the early recognition and treatment of a patient with STEMI
- Describe the criteria for system activation for managing of a “STEMI patient” Describe the standardized process to follow for STEMI management in the ED
- Describe the importance of communication and transfer of accountability between care providers

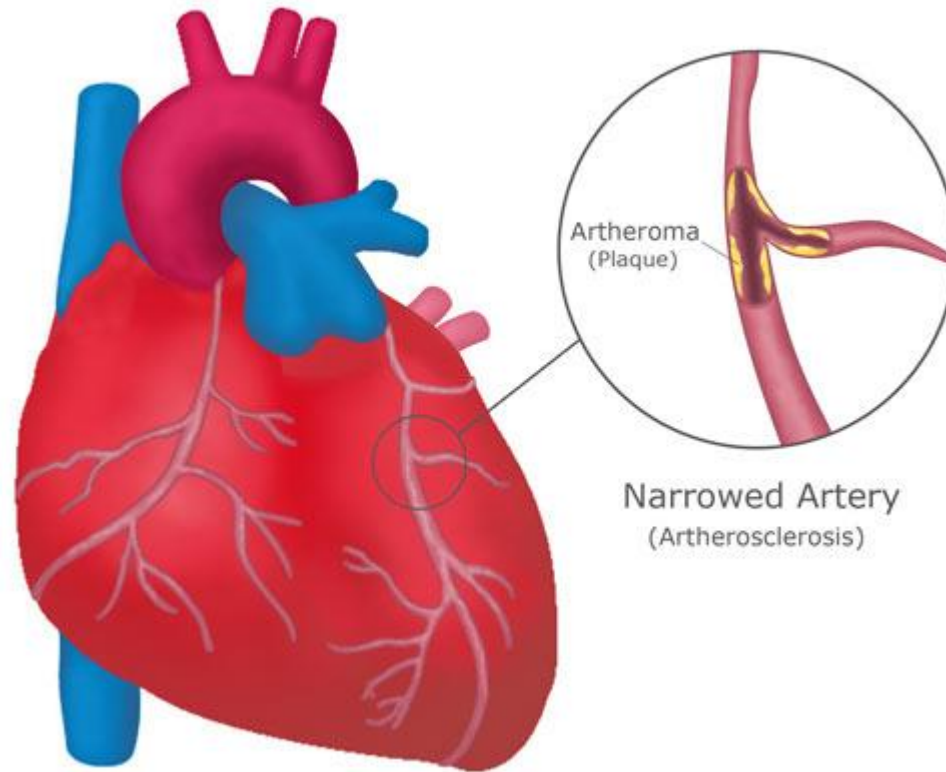




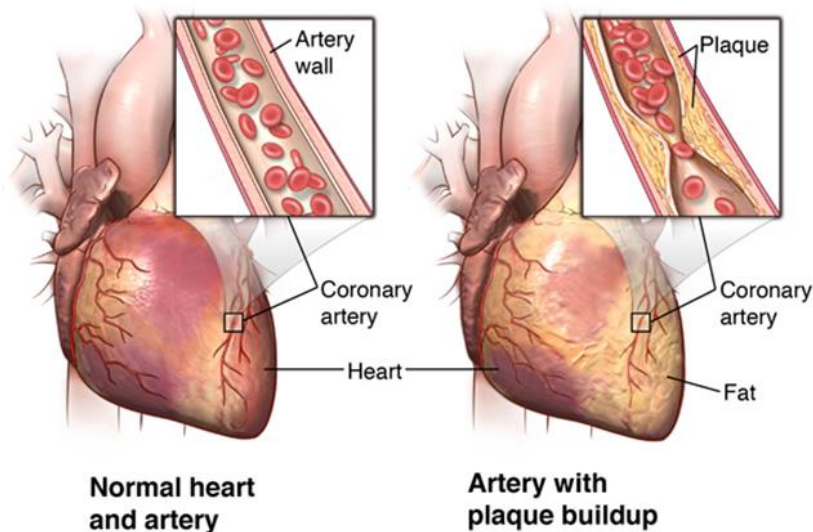
Coronary Artery Disease (CAD)



Coronary Artery Disease



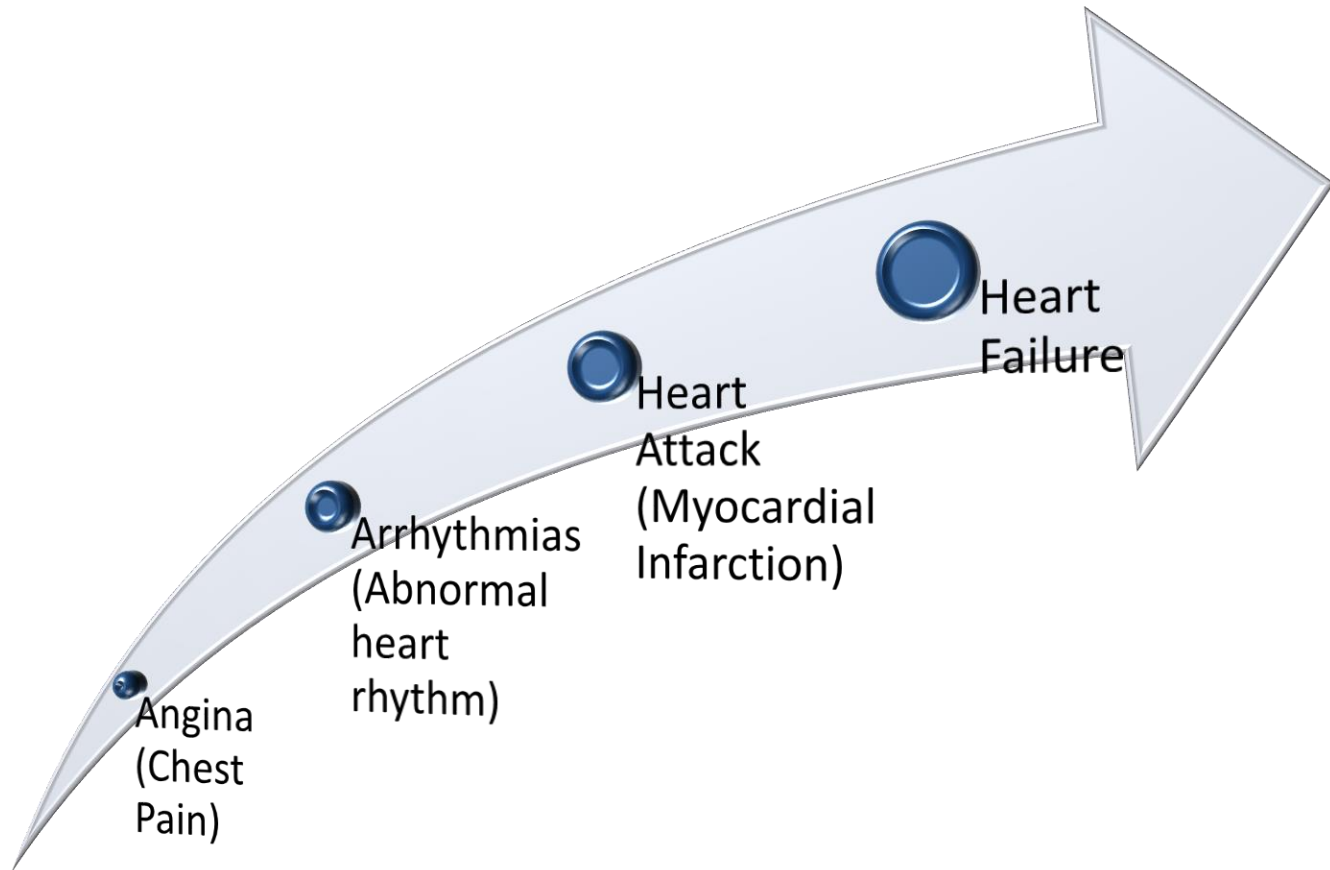
CAD: Definition



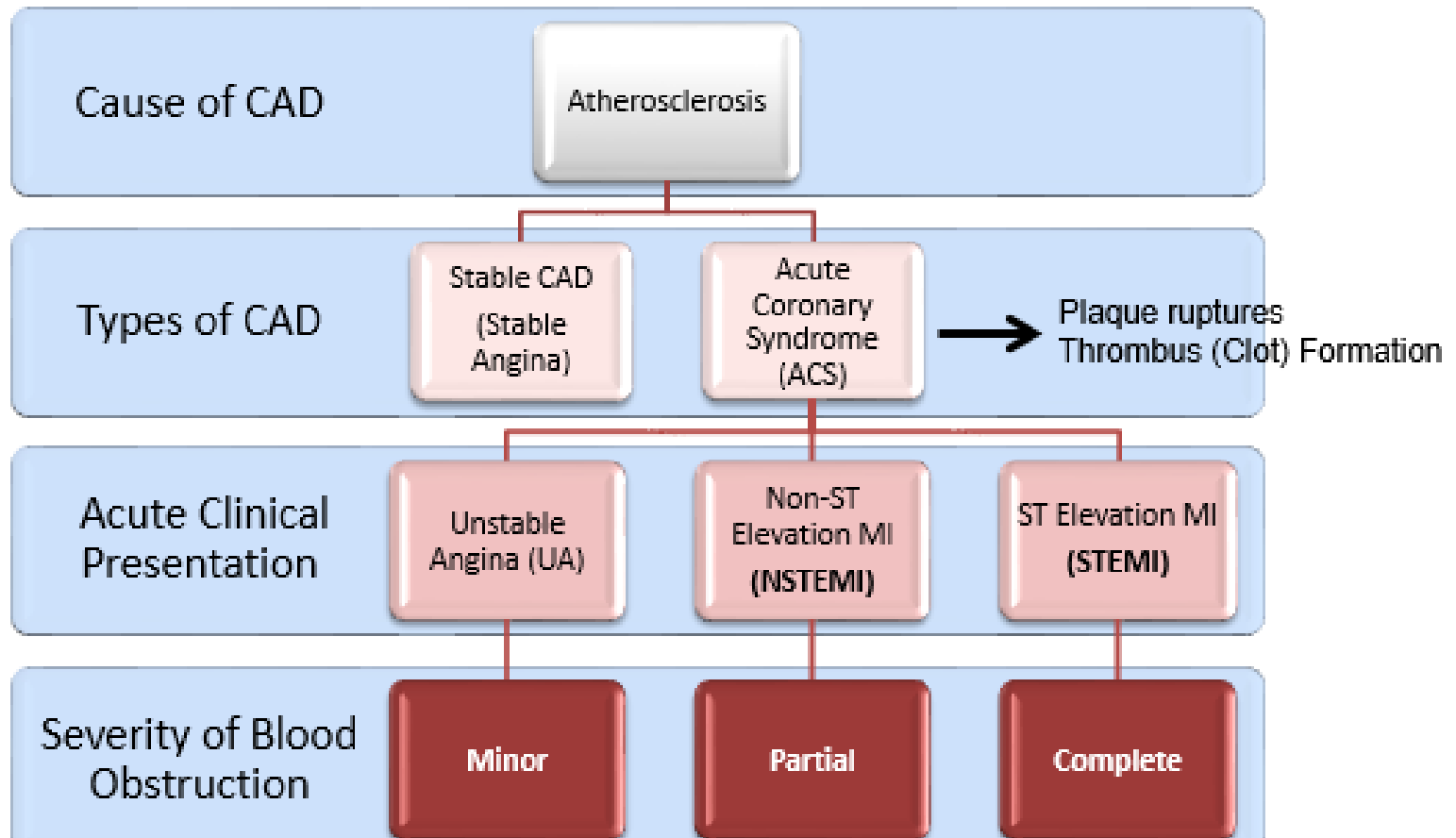
- CAD is the most common type of heart disease. It is the leading cause of death in North America in both men and women
- Atherosclerosis: buildup of a material called 'plaque' on their inner walls
- CAD occurs when the coronary arteries become hardened and narrowed



CAD : Consequence

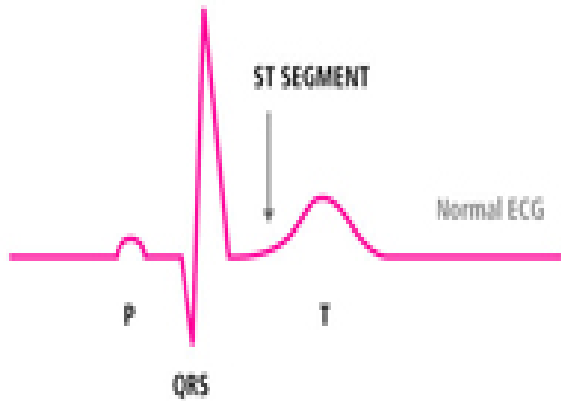


CAD: Development

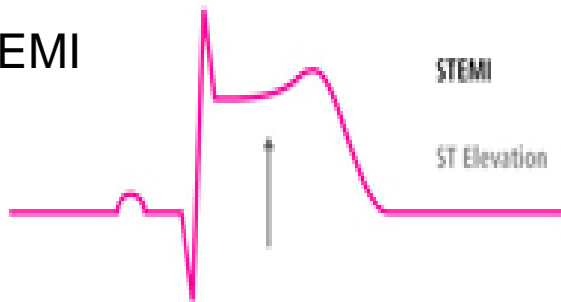


What Does a STEMI Look Like?

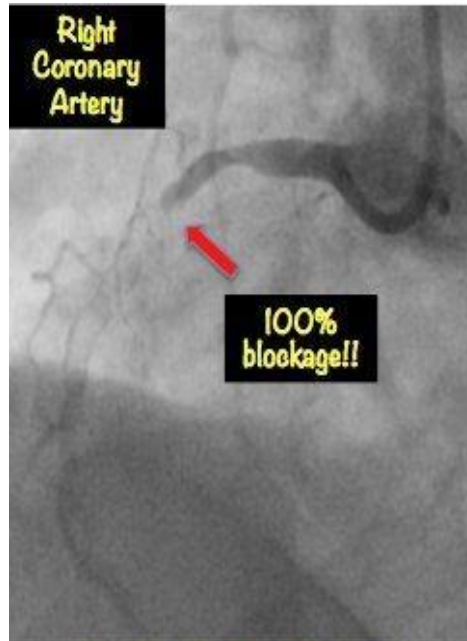
Normal ECG



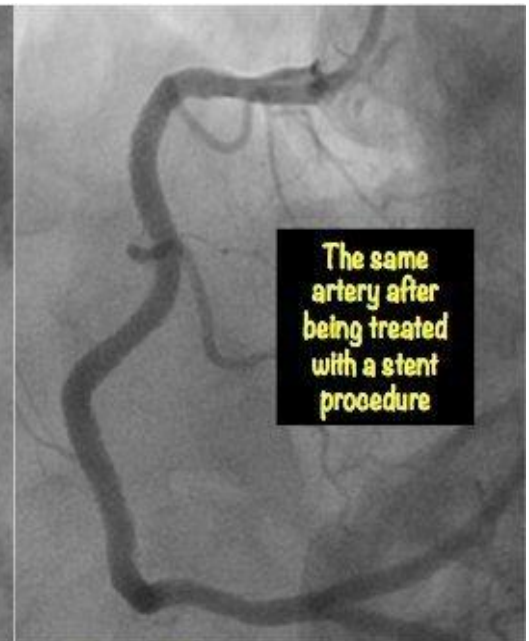STEMI



STEMI



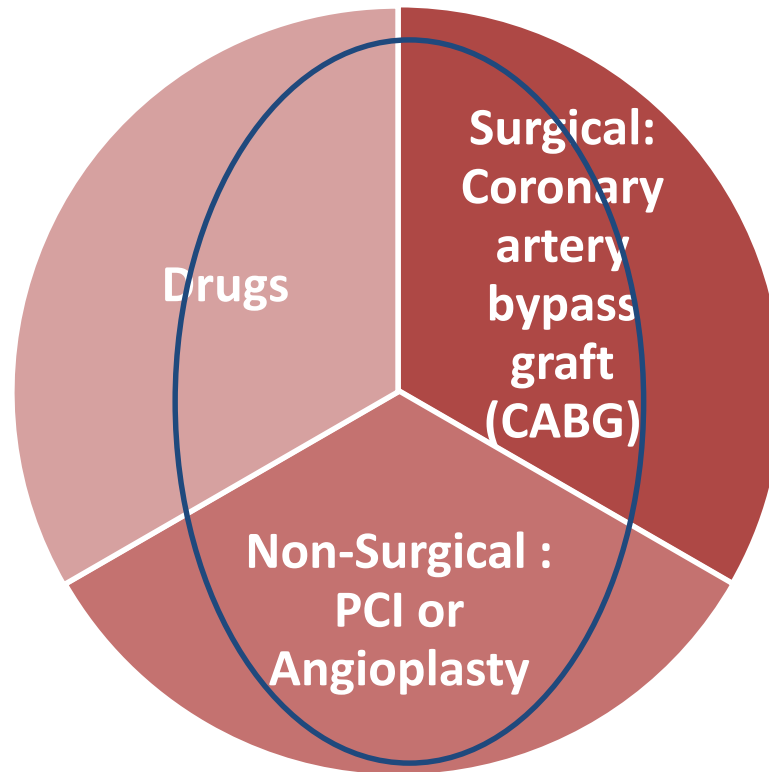
Post PCI intervention



Totally blocked artery leading to a major heart attack



Coronary Artery Disease (CAD) : Types of Treatment



Medical Treatment

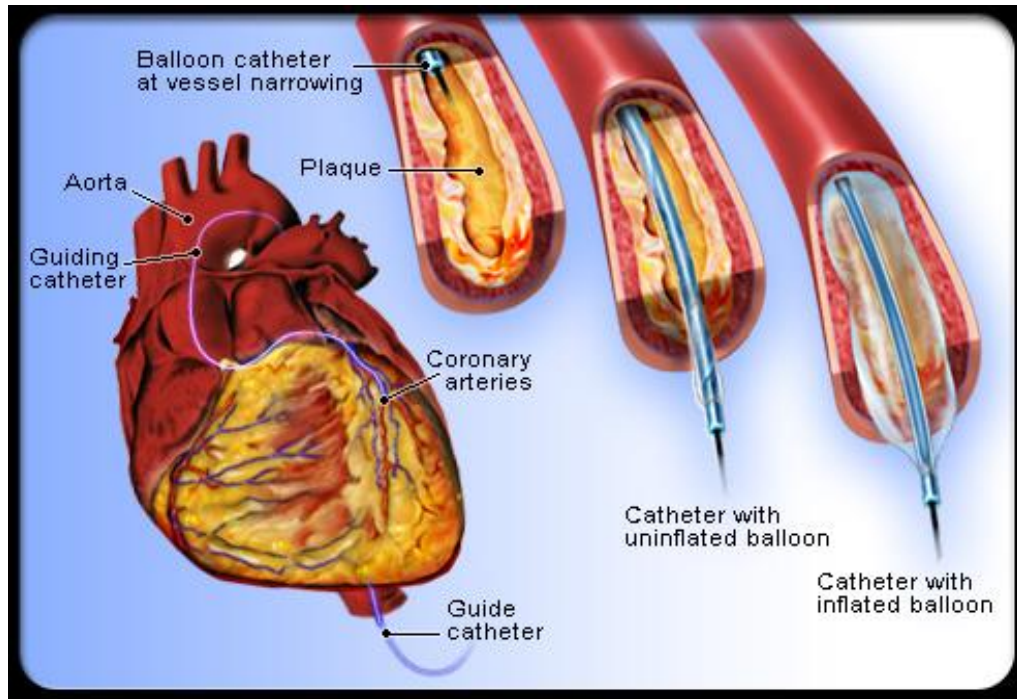
Drugs:

- Aspirin
- Antiplatelet (clopidogrel,ticagrelor,prasugrel)
- Beta blocker
- Ace inhibitor
- Statin or lipid-lowering drugs

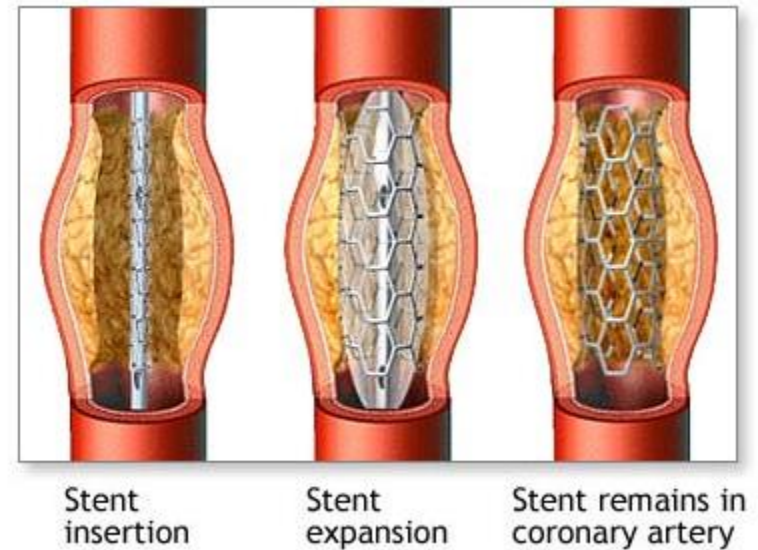


PCI Treatment

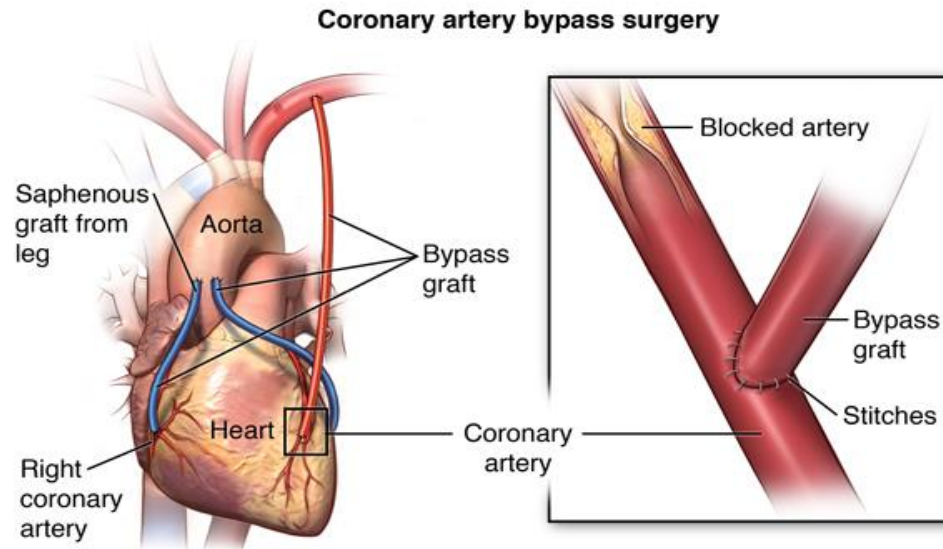
Percutaneous coronary intervention
(PCI or angioplasty)



PCI with Stent



Coronary Artery Bypass Graft (CABG)



- A surgical procedure to treat the blocked or narrowed arteries by creating a 'bypass' for the blocked portion of the coronary artery using either a vein (e.g., saphenous vein) or artery (e.g., left internal mammary artery, radial artery).



Your Role

As a healthcare provider YOU have the opportunity to make a difference in the lives of many; you play an important role in the success of a hospital STEMI program.

Goal:

ED staff to use the information in this presentation to deliver care based on best practice guidelines:

- Early recognition of STEMI ACS patients and initiate timely evaluation and intervention
- Coordinate practices between paramedic services and PCI hospital
- Promote and encourage quality improvement process at your hospital to improve STEMI performance





ED STEMI Protocol



ED STEMI Protocol Key Messages

- It is recognized that across Ontario, there are well established regional and LHIN wide STEMI protocols, transfer agreements and partnerships with ED's, paramedic services and PCI hospitals
- These robust networks serve as a hub and spoke model and **will continue in their current form**
- The ED STEMI initiative builds on the current system to support the networks and close the gaps
- The initiative reinforces ED STEMI care best practices by:
 1. Reinforcing **early identification and decision making** (triage, ECG and reperfusion decision) through provincial education, provision of tools and templates
 2. Identifying ED's **without a current relationship** to their closest PCI hospital and supporting them to develop protocols and networks
 3. Reinforcing reperfusion strategies by **designating an ED's reperfusion strategy** for non PCI hospitals as either primary PCI (< 60 mins drive time) or pharmacoinvasive (> 60 mins drive time)
 4. Developing and implementing provincial **STEMI performance targets**



ED STEMI Management – Reperfusion Targets

Early Identification

Chest Pain

- Triage & perform STAT ECG (Door to ECG \leq 10MIN)
- If negative, repeat ECG q10 mins x 3
- Symptoms \leq 12 hours – STEMI Diagnosis
- If Symptoms \geq 12 hrs consult Cardiologist or Internal Medicine

Reperfusion Decision

Primary PCI **OR** Pharmacoinvasive Strategy

For Primary PCI

- Door in Door Out Time (DIDO) \leq 30 mins
- Door to Balloon Time (D2B) \leq 120 mins

Pharmacoinvasive

- Door to Needle Time (D2N) \leq 30 mins
- Transfer to PCI hospital \leq 24 hrs



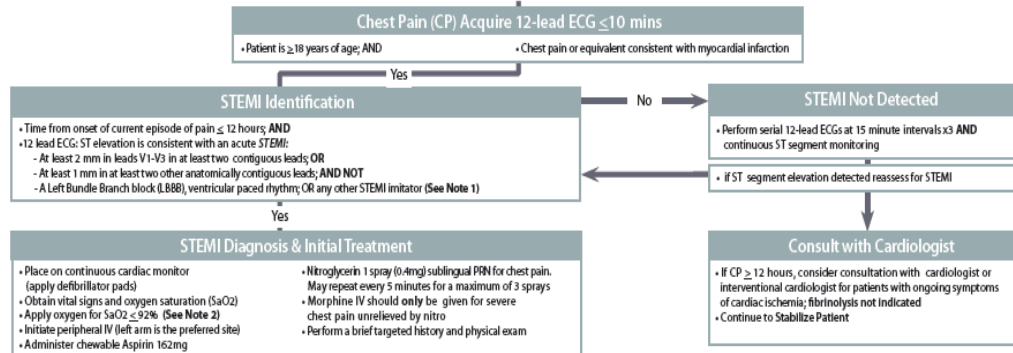
Ontario ED STEMI Algorithm

CARDIAC CARE NETWORK

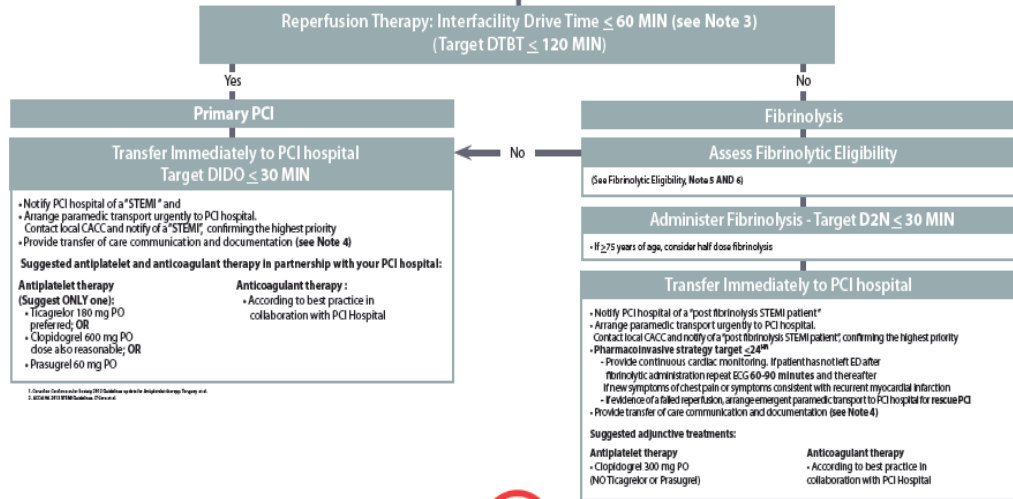


EMERGENCY DEPARTMENT STEMI ALGORITHM

EARLY RECOGNITION



EARLY REPERFUSION



ADDITIONAL NOTES



CARDIAC CARE NETWORK









Signs and Symptoms of a Heart Attack







- Chest pain is the most common symptom, but some people don't experience this.... women are less likely to experience chest pain than men

HEART ATTACK WARNING SIGNS

MEN

- Chest pain/discomfort 
- Rapid or irregular heartbeat 
- Feeling dizzy, faint or light-headed 
- Breaking out in a cold sweat 
- Stomach discomfort or indigestion 
- Shortness of breath 

WOMEN

- Chest pressure 
- Unusual fatigue for several days 
- Anxiety and sleep disturbances 
- Back, neck, arm or jaw pain 
- Nausea, feeling sick to stomach 
- Shortness of breath 

If you have any of these signs, don't wait.
Call 911

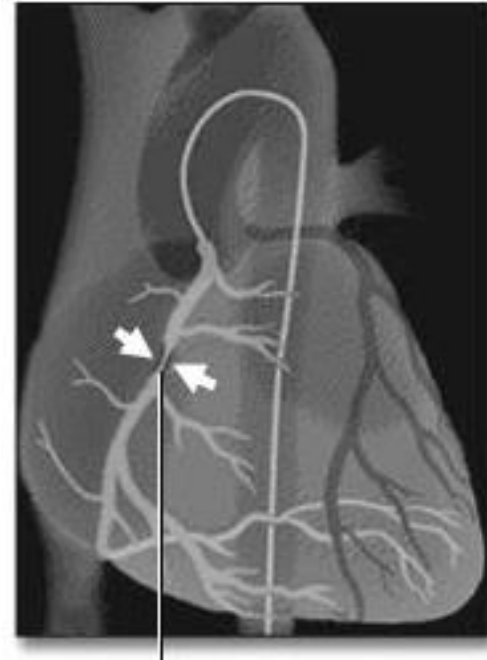froedtert.com/heart



Rapid Triage is the Key

Early identification  appropriate triage  early revascularization

- Rapid triage of patients complaining of chest pain
- Initiate the STEMI protocol
- Acquire ECG
- Activating the STEMI response team
(e.g., CODE STEMI, STEMI Alert)
- Initiate reperfusion strategy
 - Primary PCI
 - Pharmacoinvasive



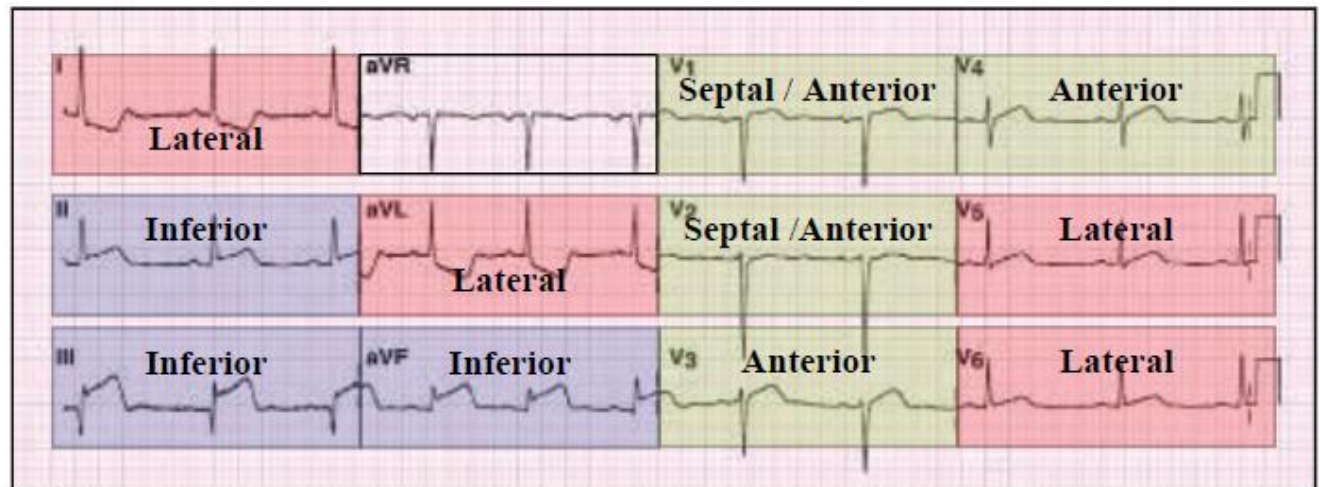
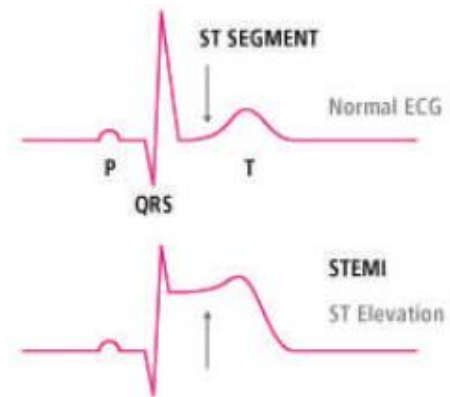
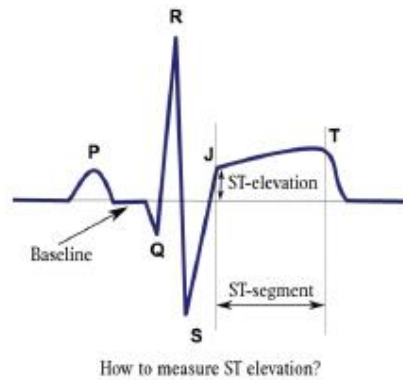
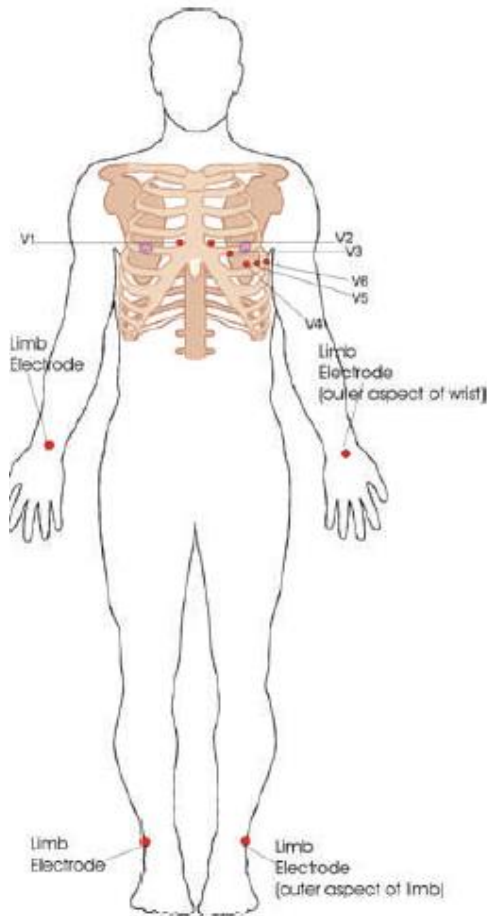
Early ECG: Target ≤ 10 Minutes

Rapid ECG  Early diagnosis  Early activation of STEMI response team

- Acquiring the ECG **within 10 minutes of ED arrival** is the first step of STEMI recognition and treatment



STEMI Recognition Essentials of the 12 Lead ECG



Activate STEMI Protocol Immediately

- Early activation of a “STEMI response team” is essential to achieving the defined reperfusion target for your hospital:
 - Primary PCI = door in door out (**DIDO**) **≤30 minutes**
 - Pharmacoinvasive strategy = **fibrinolytic therapy followed by PCI within 24 hrs**
- Contact the PCI hospital using the hotline; the 24/7 telephone number or paging system that is available for activation
- Initiate immediate transfer



Provide Key Transfer of Care Information

Transfer of care and communication to the Cardiologist or Interventional Cardiologist at PCI hospital helps in the management of the STEMI

- Time of symptom onset
- Qualifying ECG
- If ROSC state time
- Hemodynamic status
- History of AMI/PCI/CABG
- Medications given and procedures
- Copy of ECG



ED Quick Reference Pocket Card

This STEMI pocket card can be used as a quick reference tool for the management of STEMI along with the key clinical information exchange between ED staff and the cardiologist at crucial points in transfers of care

CARDIAC CARE NETWORK
Emergency Department STEMI Prompt

Early Recognition
CP \leq 12 hours

Early Interpretation
12-lead ECG (\leq 10 minutes)

Early Identification
STEMI interpretation; Initiate ACS protocol;
(Door in door out \leq 30 min)


Early Notification

- Activate STEMI protocol
- Transfer to PCI hospital within the target time

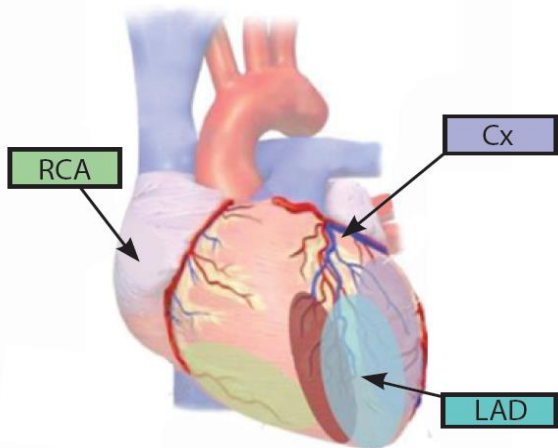
Early Reperfusion
Door-to-needle time \leq 30 min
Door-to-balloon time \leq 90min
Door-to-balloon time for transfers: non PCI centre $<$ 120 min

Transfer of Care and Communication to Interventional Cardiologist

- Time of symptom onset
- Qualifying ECG
- Time of ROSC
- Hemodynamic status
- History of AMI/PCI/CABG
- Medications given and procedures
- Copy of ECG



Anatomy of the heart with localizing infarct territories.



I Lateral	aVR	V1 Septal	V4 Anterior
II Inferior	aVL Lateral	V2 Septal	V5 Lateral
III Inferior	aVF Interior	V3 Anterior	V6 Lateral



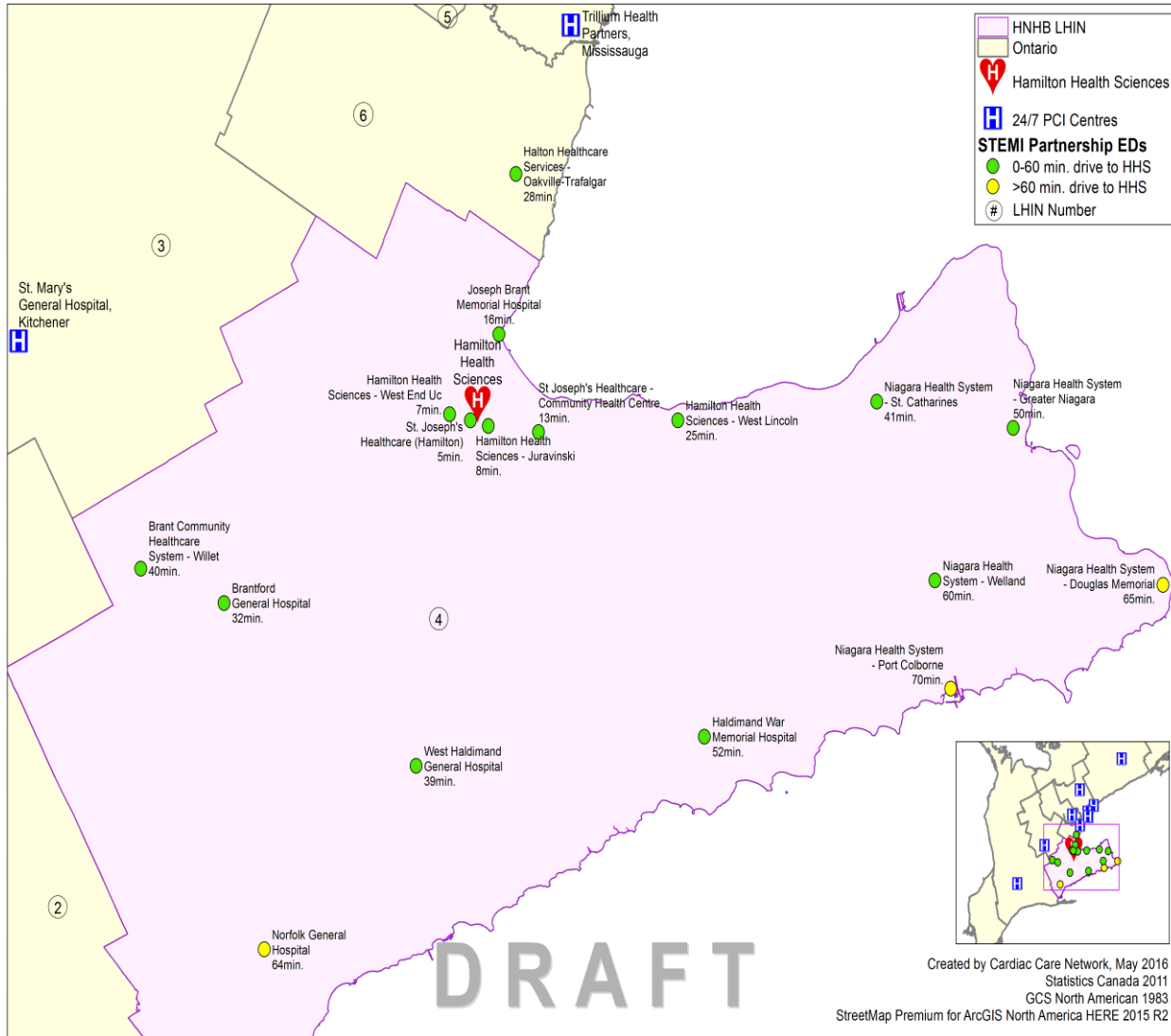
Geographical Partnership Maps

Purpose:

- To identify PCI and non-PCI hospital partnerships (each hospital will receive)
- Reinforce the reperfusion strategies by **designating an ED's reperfusion strategy** for non-PCI hospital as either:
 - primary PCI (< 60 mins drive time) or;
 - pharmacoinvasive (> 60 mins drive time)
- Provide contact information to promote opportunities for greater communication and mentorships



PCI and Non-PCI Partnership Mapping with Defined Reperfusion Strategy

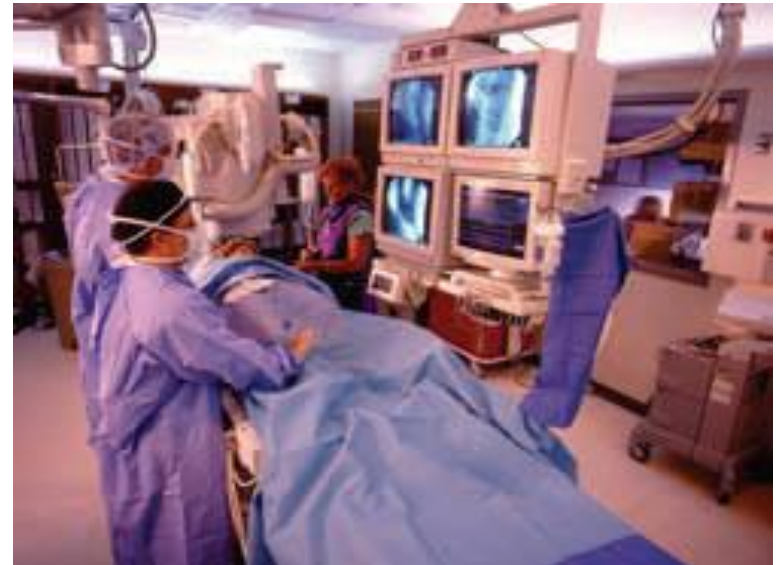
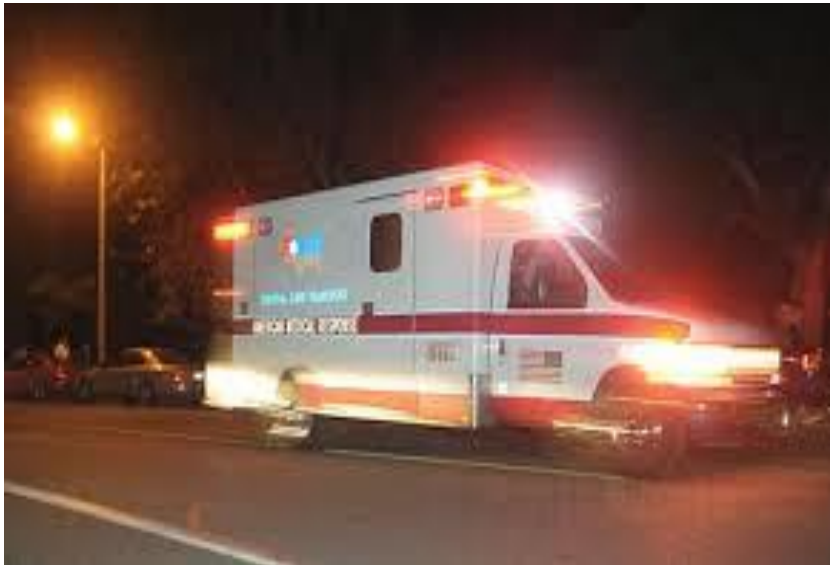
ED LHIN	Non PCI Hospital Partnership with Hamilton Health Sciences (HHS)	Drive Mins to HHS	Reperfusion Strategy:
HNHB	St. Joseph's Healthcare (Hamilton)	5	Primary PCI
HNHB	Hamilton Health Sciences - West End Uc	7	Primary PCI
HNHB	Hamilton Health Sciences - Juravinski	8	Primary PCI
HNHB	St Joseph's Healthcare - Community Health Centre	13	Primary PCI
HNHB	Joseph Brant Memorial Hospital	16	Primary PCI
HNHB	Hamilton Health Sciences - West Lincoln	25	Primary PCI
MH	Halton Healthcare Services - Oakville-Trafalgar	28	Primary PCI
HNHB	Brantford General Hospital	32	Primary PCI
HNHB	West Haldimand General Hospital	39	Primary PCI
HNHB	Brant Community Healthcare System - Willet	40	Primary PCI
HNHB	Niagara Health System - St. Catharines	41	Primary PCI
HNHB	Niagara Health System - Greater Niagara	50	Primary PCI
HNHB	Haldimand War Memorial Hospital	52	Primary PCI
HNHB	Niagara Health System - Welland	60	Primary PCI
HNHB	Norfolk General Hospital	64	Pharmacoinvasive
HNHB	Niagara Health System - Douglas Memorial	65	Pharmacoinvasive
HNHB	Niagara Health System - Port Colborne	70	Pharmacoinvasive



Primary PCI

- **Rapid transport to a PCI hospital**
- Send the patient to the cath lab immediately: target **ED DIDO ≤30 minutes**
- Interfacility transport (with paramedic lights and sirens): **drive time ≤60 minutes**

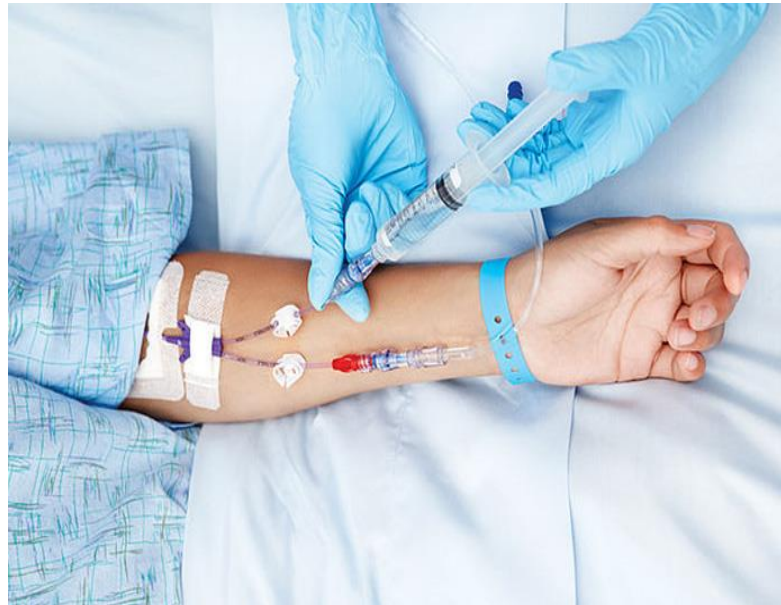

[PCI Procedure](#)



Pharmacoinvasive

- Administer fibrinolytic reperfusion therapy: **target ≤ 30 minutes of ED arrival**
- Arrange immediate transport to PCI hospital in parallel to fibrinolytic administration i.e., **“drip and ship”**
- Notify PCI hospital immediately
- Transfer to PCI hospital: **target ≤ 24 hours of ED arrival**





Appendix





STEMI Case Scenarios

Case 1: Primary PCI

55 year old woman walks in to a non-PCI ED within 2 hours of chest pain onset

ED protocol:

- **ECG is acquired within 10 minutes** which shows inferior ST elevation
- Assessed, given aspirin 162 mg chewable po
- PCI hospital is 30 minutes away, there is an established STEMI protocol between paramedic services and the PCI hospital for rapid transfer
- **STEMI activation by ED as per local process** informs the interventional cardiologist (IC) at the PCI hospital and paramedic services
- Antiplatelet therapy is administered
- Anticoagulation is given as established by the PCI hospital
- **DIDO is <30 minutes**

Suggested antiplatelet therapies: Ticagrelor 180mg PO (**preferred**) or Clopidogrel 600mg PO (alternate)

Suggested anticoagulation therapies:

- According to PCI hospital within network (**each non-PCI hospital should be linked to a PCI hospital**)



Inferior STEMI

- Inferior myocardial infarctions (MI) account for 40-50% of all MIs
- Generally have a more favourable prognosis than anterior MI
- Up to 40% of patients with an inferior STEMI will have a concomitant [right ventricular infarction](#). These patients may develop severe hypotension in response to nitrates and generally have a worse prognosis
- Up to 20% of patients with inferior STEMI will develop significant bradycardia due to [second-](#) or [third-degree](#) AV block. These patients have an increased in-hospital mortality
- Inferior STEMI may also be associated with [posterior infarction](#), which confers a worse prognosis due to increased area of myocardium at risk



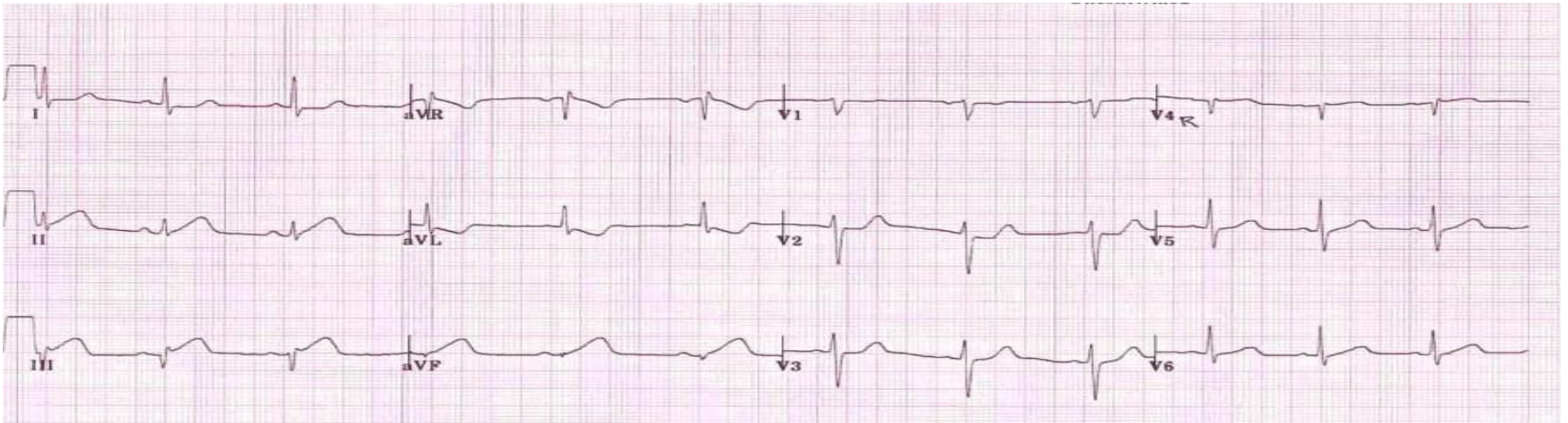
How to Recognise an Inferior STEMI

- ST elevation in leads II, III and aVF
- Progressive development of Q waves in II, III and aVF
- Reciprocal ST depression in aVL (\pm lead I)

- ST elevation in lead III $>$ lead II
- Presence of reciprocal ST depression in lead I
- Signs of [right ventricular infarction](#): STE in V1 and V4R



Example 1: Inferior STEMI Interpretation

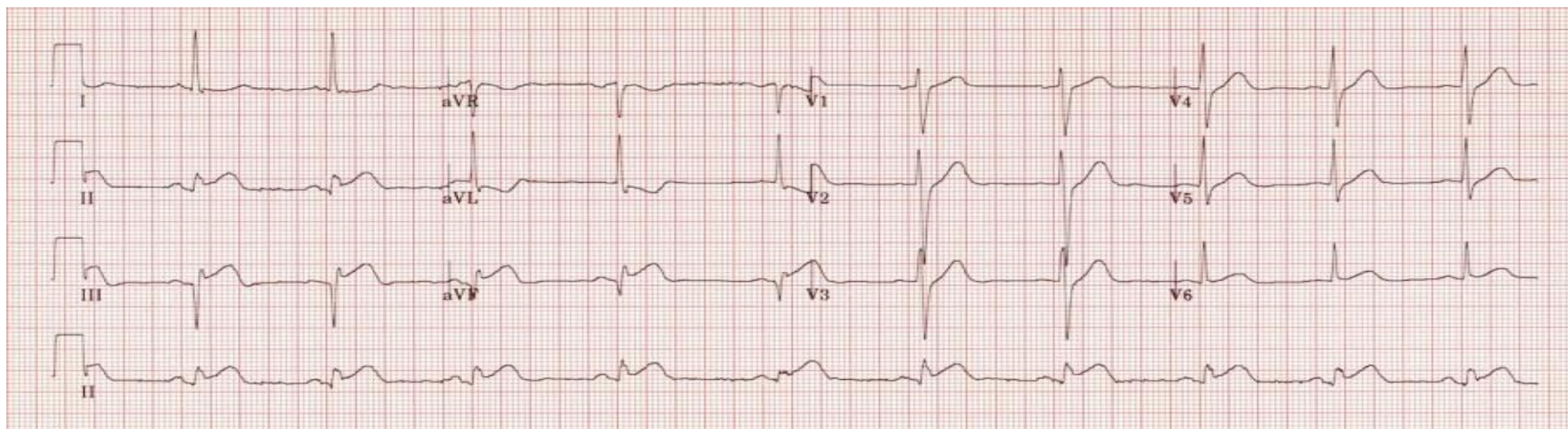


What do you see?

- Hyperacute (peaked) T waves in II, III and aVF with relative loss of R wave height
- Early ST elevation and Q-wave formation in lead III
- Reciprocal ST depression and T wave inversion in aVL
- ST elevation in lead III > lead II suggests an RCA occlusion; the subtle ST elevation in V4R would be consistent with this



Example 2: Inferior STEMI Interpretation

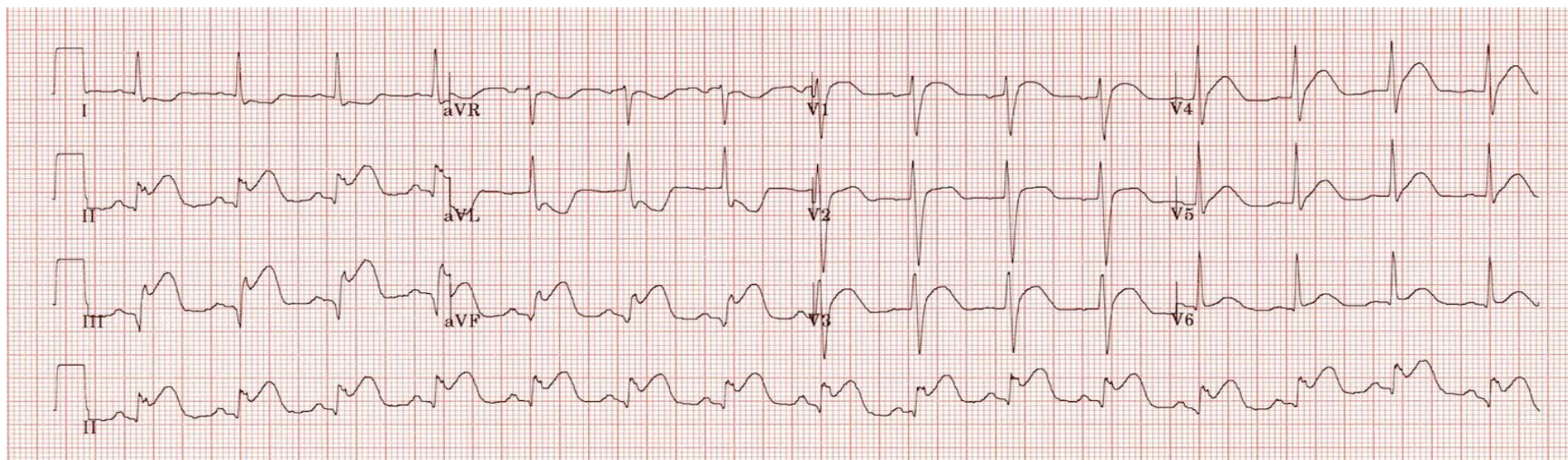


What do you see?

- ST elevation in II, III and aVF
- Q-wave formation in III and aVF
- Reciprocal ST depression and T wave inversion in aVL
- ST elevation in lead II = lead III and absent reciprocal change in lead I (isoelectric ST segment) suggest a circumflex artery occlusion



Inferior STEMI Interpretation



What do you see?

- Marked ST elevation in II, III and aVF with early Q-wave formation
- Reciprocal changes in aVL
- ST elevation in lead III > II with reciprocal change present in lead I and ST elevation in V1-2 suggests RCA occlusion with associated RV infarction
- This patient should have right-sided leads to confirm this



Case 2: Primary PCI with Fibrinolytic Absolute or Relative Contraindications

76 year old man walks in to a non-PCI ED 7 hours after symptom onset

ED protocol:

- ECG acquisition is done within 10 minutes of arrival
- Immediate assessment, given aspirin 162mg chewable po
- ECG shows a large anterior STEMI
- He has a contraindication to fibrinolytic therapy and is in heart failure (placed on BIPAP)
- Emergent transport is arranged
- Nearest PCI site is 2 hrs away, IC at PCI hospital is contacted immediately for discussion
- Patient is stabilized for transport and transferred for primary PCI

Suggested antiplatelet therapies: Ticagrelor 180mg PO (**preferred**) or Clopidogrel 600mg PO (alternate)

Suggested anticoagulation therapies:

- According to PCI hospital within network (**each non-PCI hospital should be linked to a PCI hospital**)



Anterior STEMI

Clinical Relevance:

- Anterior STEMI results from occlusion of the [left anterior descending artery \(LAD\)](#).
- Anterior myocardial infarction carries the worst prognosis of all infarct locations, mostly due to larger infarct size

How to Recognise Anterior STEMI:

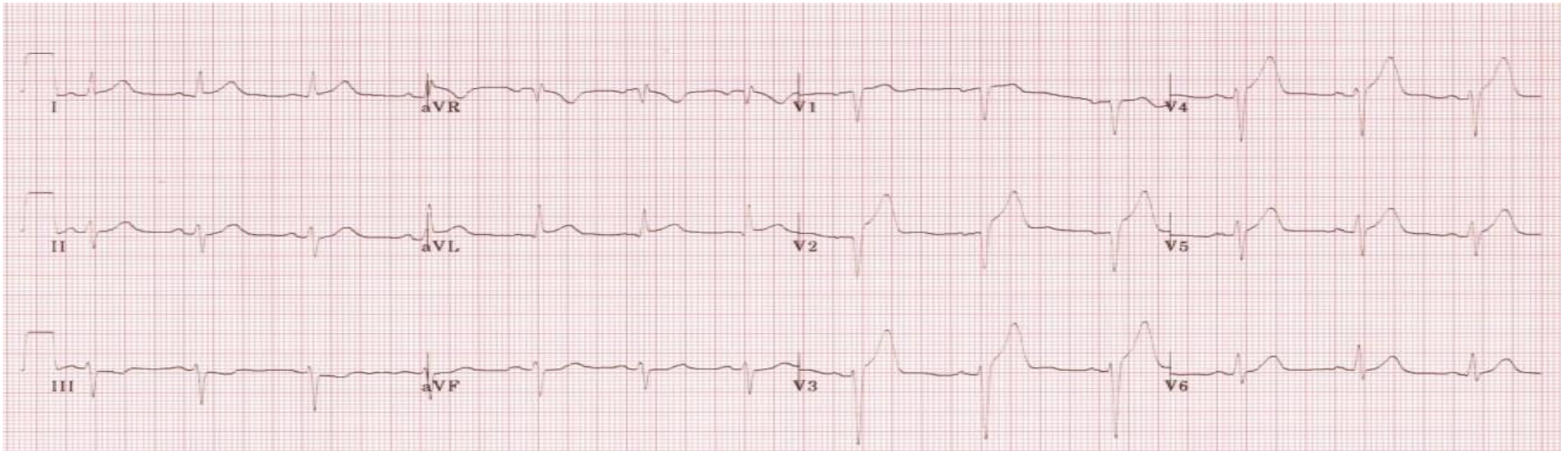
- ST segment elevation with Q wave formation in the precordial leads (V1-6) ± the high lateral leads (I and aVL)
- Reciprocal ST depression in the inferior leads (mainly III and aVF)

Infarct patterns are named according to the leads with maximal ST elevation:

- Septal = V1-2
- Anterior = V2-5
- Anteroseptal = V1-4
- Anterolateral = V3-6, I + aVL
- Extensive anterior/anterolateral = V1-6, I + aVL



Anterior STEMI

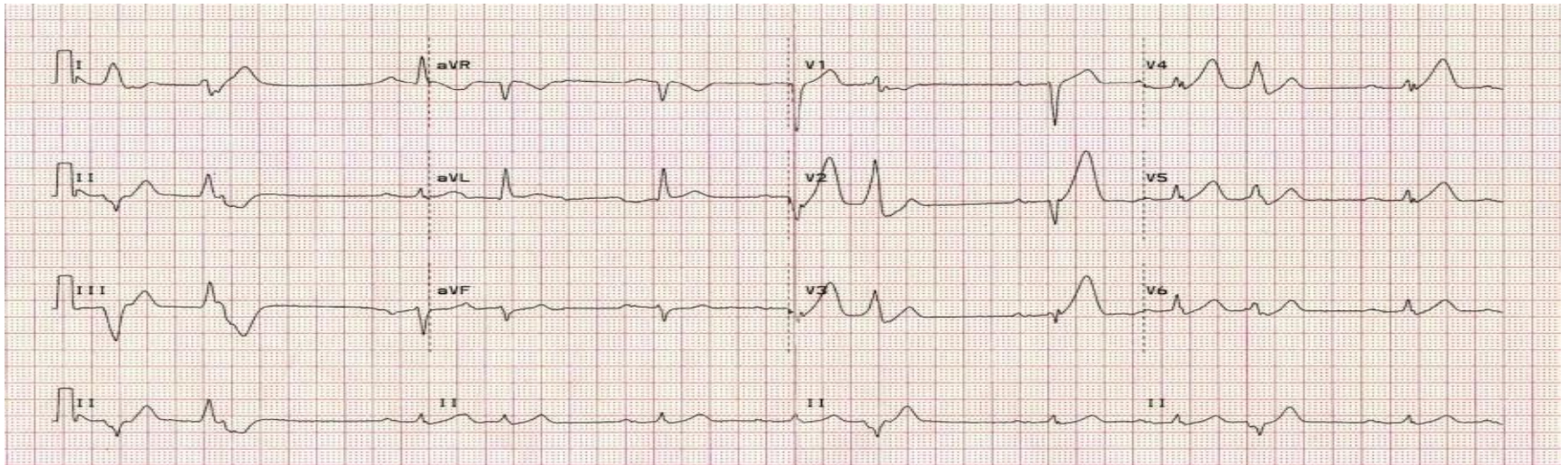


What do you see?

- ST elevation is maximal in the anteroseptal leads (V1-4)
- Q waves are present in the septal leads (V1-2)
- There is also some subtle STE in I, aVL and V5, with reciprocal ST depression in lead III
- There are hyperacute (peaked) T waves in V2-4
- These features indicate a hyperacute anteroseptal STEMI



Anterior STEMI

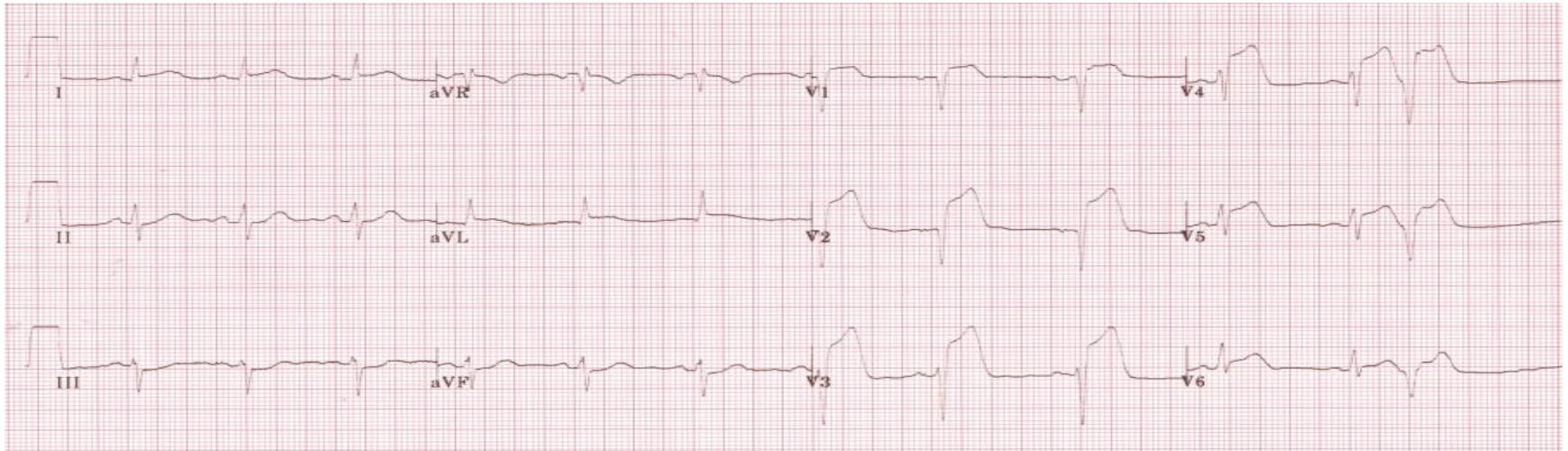


What do you see?

- Hyperacute T-waves in V2-6 (most marked in V2 and V3) with loss of R wave height
- The rhythm is sinus with 1st degree AV block
- There are premature atrial complexes (beat 4 on the rhythm strip)
- There are multifocal ventricular ectopy (PVCs of two different types) indicating an “irritable” myocardium at risk of ventricular fibrillation



Anterior STEMI

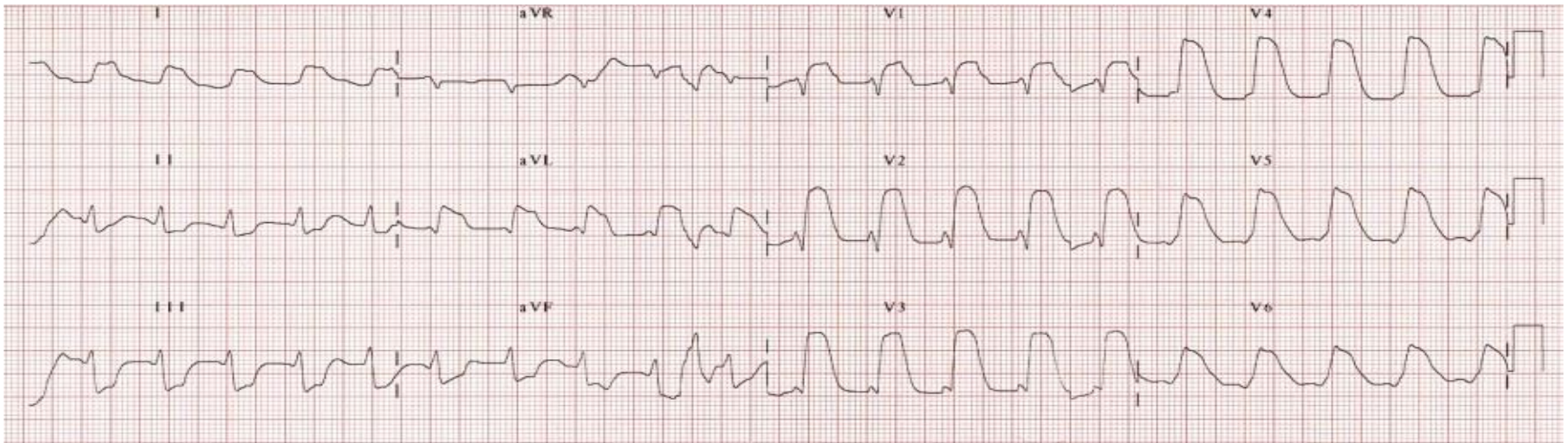


What do you see?

- ST elevation in V1-6 plus I and aVL (most marked in V2-4).
- Minimal reciprocal ST depression in III and aVF
- Q waves in V1-2, reduced R wave height (a Q-wave equivalent) in V3-4
- There is a premature ventricular complex (PVC) with “R on T” phenomenon at the end of the ECG; this puts the patient at risk for ventricular arrhythmias



Anterior STEMI



What do you see?

- Massive ST elevation with “tombstone” morphology is present throughout the precordial (V1-6) and high lateral leads (I, aVL)
- This pattern is seen in proximal LAD occlusion and indicates a large territory infarction with a poor LV ejection fraction and high likelihood of cardiogenic shock and death



Case 3: Fibrinolytic Administration :Pharmacoinvasive Treatment

45 year old man presents to non-PCI hospital via paramedic services as the nearest PCI hospital is 3 hours away

ED protocol:

- Paramedic qualifying ECG shows a lateral ST elevation
- Paramedic services notify the non PCI hospital of STEMI patient enroute, there are no contraindications to fibrinolytic therapy
- Fibrinolysis is administered with a door to needle (**D2N**) **time of ≤ 30 minutes**
- The appropriate antiplatelet and anticoagulation (as per agreement with PCI hospital)
- Interventional cardiologist (IC) at the PCI site is contacted and informed a fibrinolytic has been administered along with the transfer of care information



Case 3 continued...

- Immediate transfer arrangements are made with a CTAS 2 assignment to PCI hospital **within 24 hrs for Pharmacoinvasive PCI**
- Provide continuous monitoring and repeat the ECG at 60 minutes and 90 minutes to assess clinical reperfusion if not yet transported
- If patient shows **evidence of failed reperfusion**, arrange **emergent transfer** with a CTAS 1 assignment and inform IC at PCI hospital

Suggested antiplatelet therapies: Clopidogrel 300 mg PO for patients < 75 years old or Clopidogrel 75 mg PO for patients ≥ 75 years old; **Ticagrelor is contraindicated**

Suggested anticoagulation therapies:

- According to PCI hospital within network (**each non-PCI hospital should be linked to a PCI hospital**)



Lateral STEMI

How to Recognise a Lateral STEMI

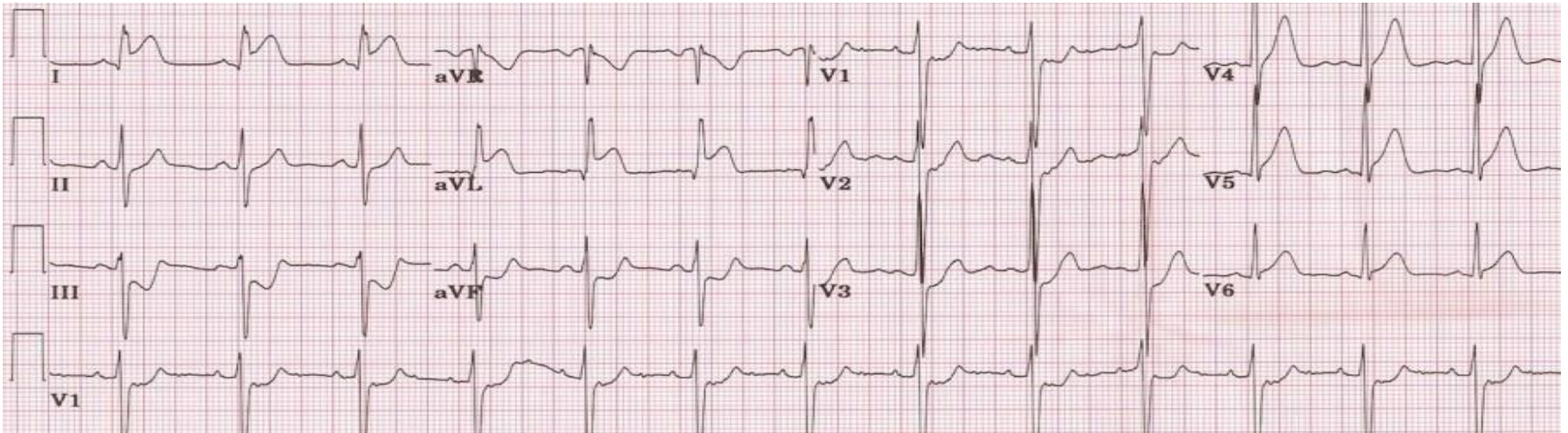
- ST elevation in the lateral leads (I, aVL, V5-6).
- Reciprocal ST depression in the inferior leads (III and aVF)

Patterns of lateral infarction:

- **Anterolateral** STEMI due to LAD occlusion
- **Inferior-posterior-lateral** STEMI due to left circumflex (LCx) occlusion
- **Isolated lateral** infarction due to occlusion of smaller branch arteries such as the diagonal 1 (D1), obtuse marginal (OM) or ramus intermedius (IM)



High Lateral STEMI

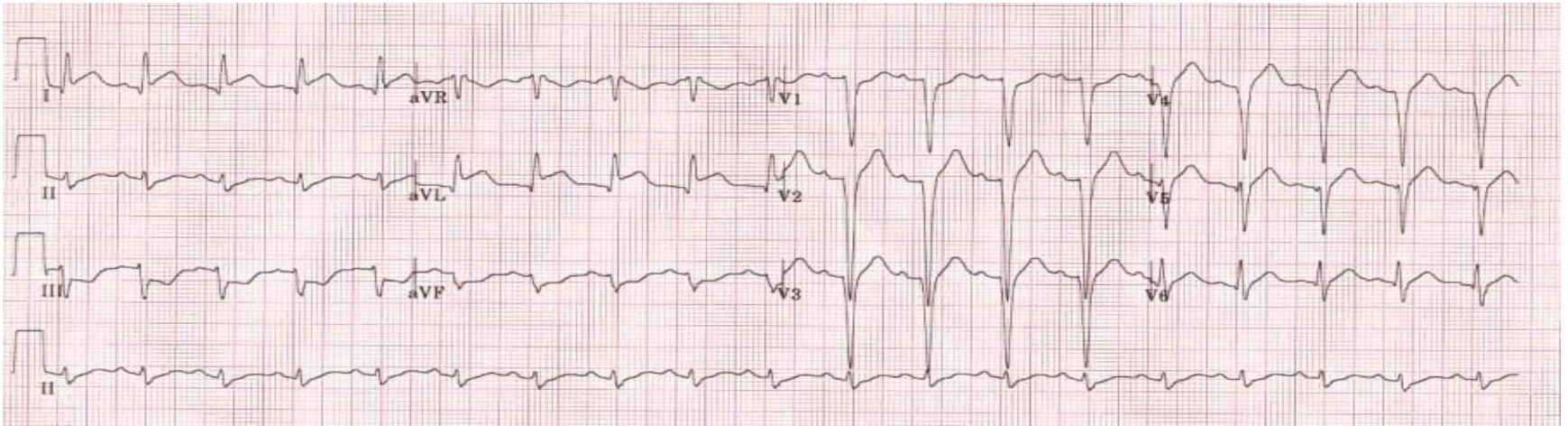


What do you see?

- ST elevation is present in the high lateral leads ,I and aVL
- There is also subtle ST elevation with hyperacute T waves in V5-6.
- There is reciprocal ST depression in the inferior leads ,III and aVF with associated ST depression in V1-3 (which could represent anterior ischemia or reciprocal change)
- This pattern is consistent with an acute infarction of the lateral wall of the left ventricle (high lateral STEMI)



High Lateral MI

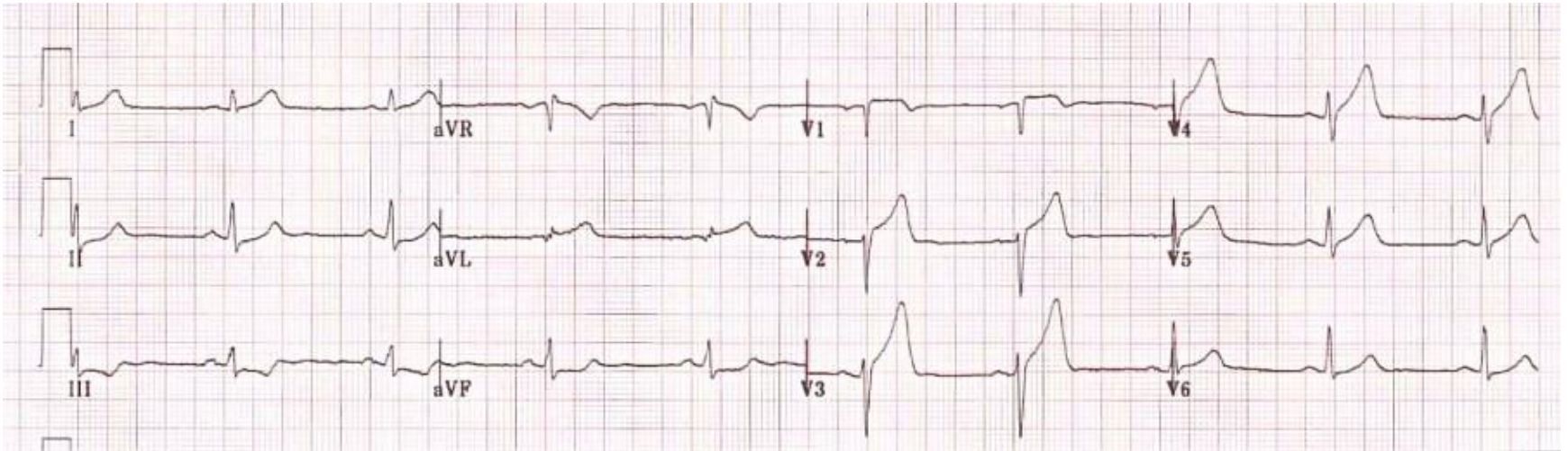


What do you see?

- ST elevation is present in the high lateral leads, I and aVL
- There is reciprocal ST depression in the inferior leads, III and aVF
- QS waves in the anteroseptal leads (V1-4) with poor R wave progression, indicates prior anteroseptal infarction
- This pattern suggests proximal LAD disease with an acute occlusion of the first diagonal branch (D1)



Anterolateral STEMI

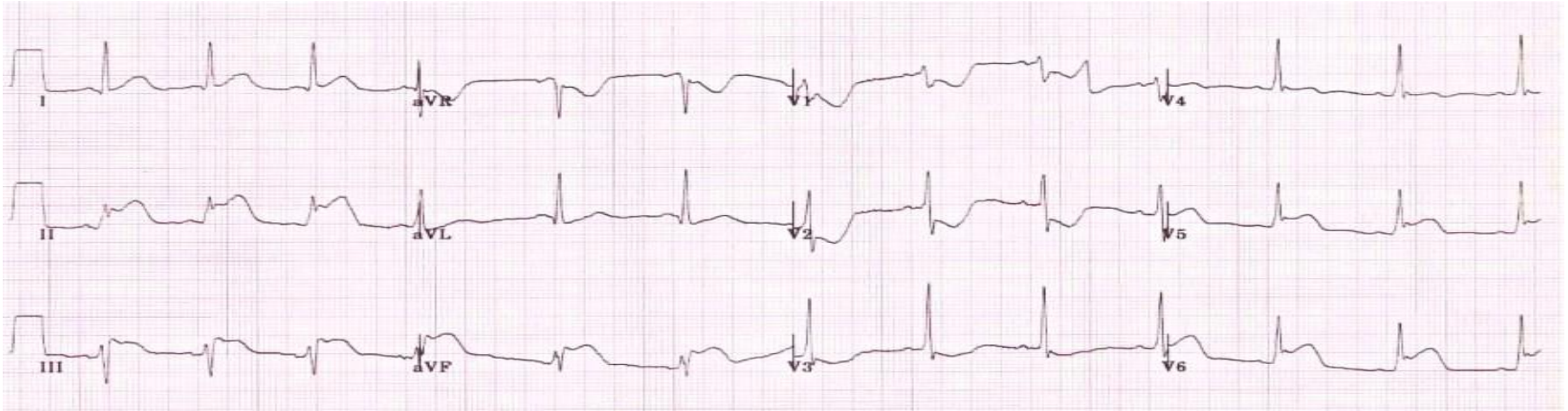


What do you see?

- There is early ST elevation with hyperacute T waves in the anteroseptal leads ,V1-4
- There is also subtle ST elevation in the high lateral leads, I and aVL
- The presence of reciprocal ST depression in the inferior leads ,III and aVF makes the lateral ST elevation more obvious
- This ECG represents the early stages of a large anterolateral infarction
- The combination of ST elevation in the precordial and high lateral leads is indicative of proximal LAD occlusion



Inferolateral STEMI



What do you see?

- There is ST elevation in the inferior (II, III, aVF) and lateral (I, V5-6) leads
- The precordial ST elevation extends out as far as V4, however the maximal STE is in V6
- ST depression in V1-3 is suggestive of associated [posterior infarction](#) (the R/S ratio > 1 in V2 is consistent with this)
- This is an acute inferolateral STEMI with probable posterior extension
- This constellation of ECG abnormalities is typically produced by occlusion
- of the proximal circumflex artery



15-Lead ECG *Clinical significance*

- It is estimated that up to 50% of inferior MIs have right ventricular and/or posterior involvement due to the RCA blood supply
- Right ventricular MIs are preload dependent for cardiac output
 - **Nitrates can further reduce preload** (use with caution)
 - Hypotension associated with **RVI responds well to IV fluid bolus**
 - Are rarely seen without inferior MI



15-Lead ECG

When should it be done?

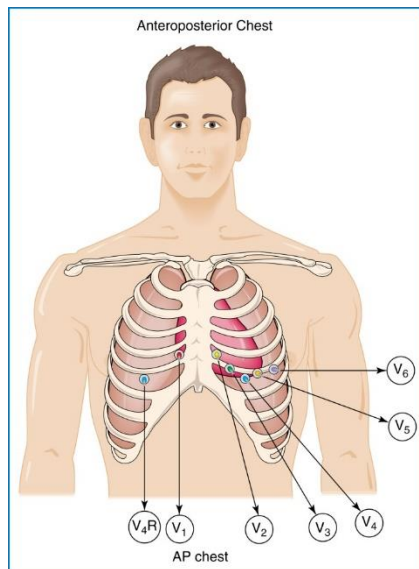
- Any patient with an inferior STEMI
- ST depression seen in V1-V3 (reciprocal changes of posterior MI)
- 12-lead ECG does not view right ventricle or posterior wall



Acquiring a 15-Lead ECG

Placement of V4R

- Acquire 12 lead ECG
- Move V4 to V4R (midclavicular, 5th intercostal space on the right side) opposite to normal V4 placement on left

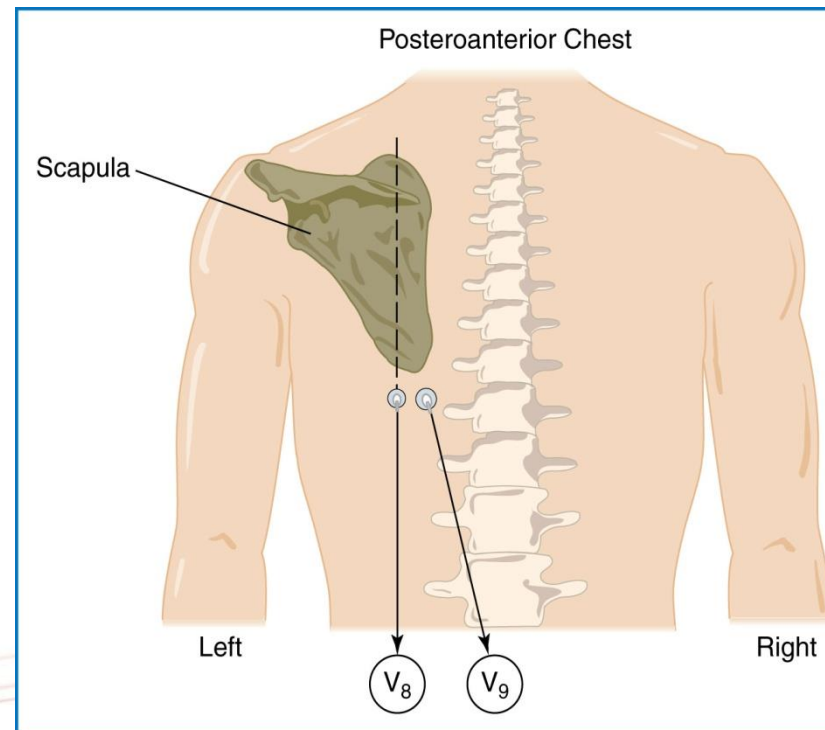


15-Lead ECG: V8, V9

Process for Acquiring a 15 Lead ECG

Placement of V8, V9

- V5 becomes V8
- V6 becomes V9
- Move V5 to V8 location (midclavicular, 5th intercostal space)
- Move V6 to V9 location (between V8 and the spine)
- Acquire a second 12 lead
- Re-label:
 - V4R, V8, V9





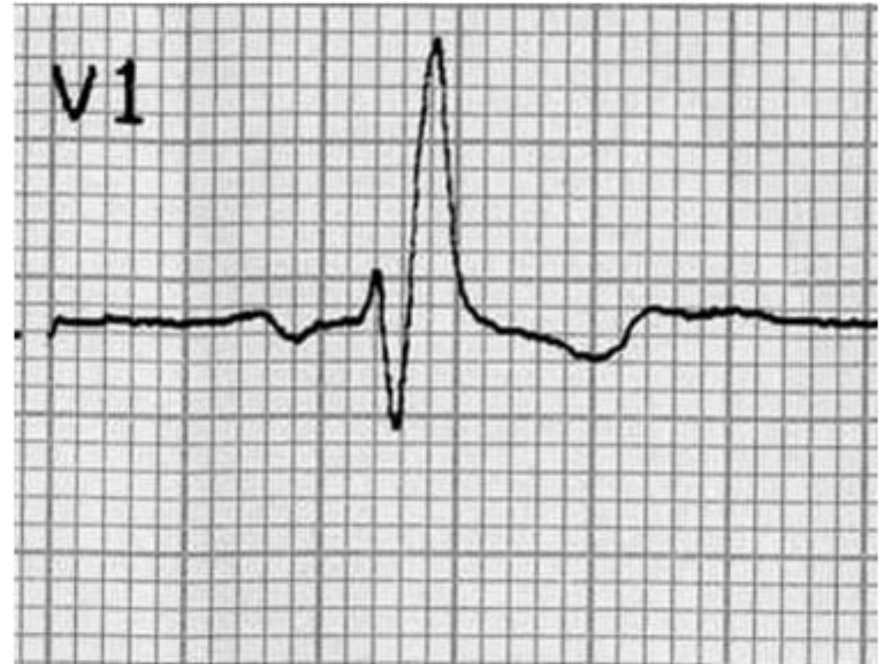
Left Bundle Branch Blocks (LBBB)

Left Bundle Branch Blocks (BBB)

- LBBB produce ECG changes that can imitate or conceal the ECG changes that are associated with Acute Coronary Syndromes (ACS)
- When a BBB is present on the 12 lead ECG try to obtain a copy of an old 12 lead ECG if possible in order to determine if the BBB is old or new

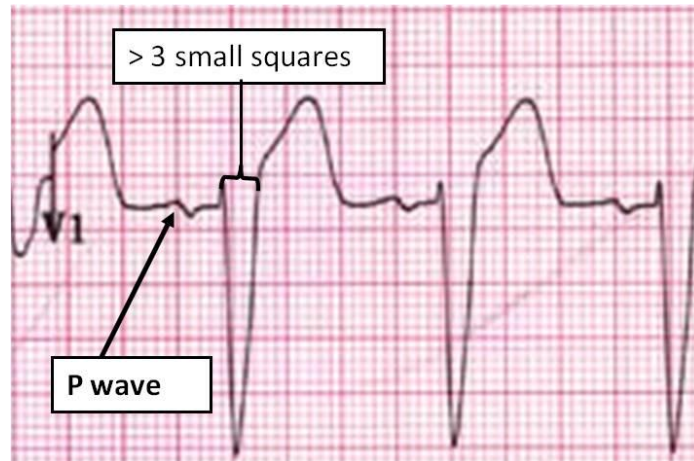
Causes:

- Aortic stenosis
- Ischaemic heart disease
- Hypertension
- Dilated cardiomyopathy
- Anterior MI
- Primary degenerative disease (fibrosis) of the conducting system (Lenegre disease)
- Hyperkalaemia
- Digoxin toxicity



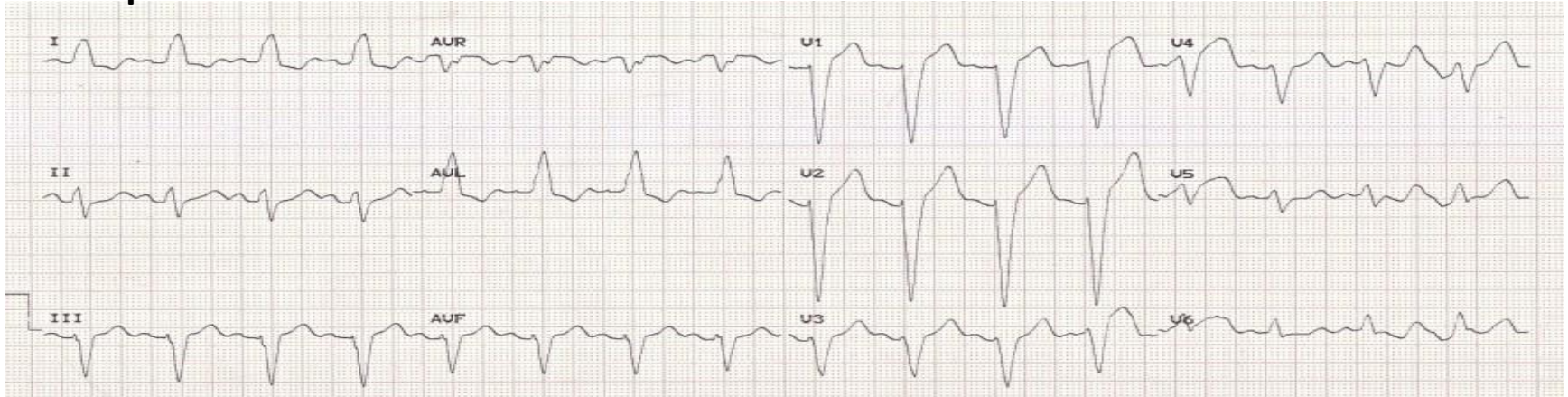
Recognition of a LBBB

- Wide QRS
(greater than 0.12 seconds or 3 small squares)
- Supraventricular rhythm
- If both of the above criteria are met suspect a BBB

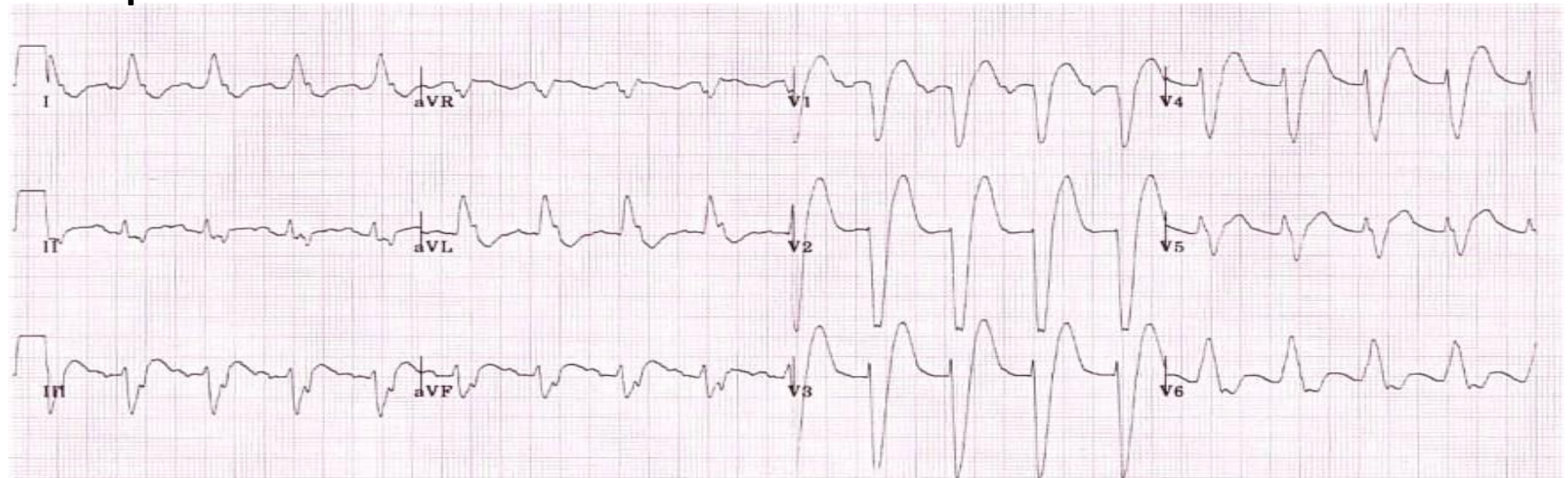


Examples of LBBB

Example 1:



Example 2:



Conditions that can Mimic or Conceal STEMI

Ventricular rhythms:

- Idioventricular rhythms
- Ventricular tachycardia
- Premature ventricular complexes

Other conditions:

- Ventricular paced rhythms
- Left ventricular hypertrophy
- Benign early repolarization
- Pericarditis
- Hyperkalemia

